



A Rare Case of Hirayama Disease Diagnosed by Dynamic MR Imaging

Hannah Mathew*; KP Ashwin

Kasturba Medical College Manipal, India.

***Corresponding Author(s): Hannah Mathew**

Kasturba Medical College, India.

Email: h2mathew@gmail.com

Received: Dec 16, 2021

Accepted: Jan 19, 2022

Published Online: Jan 24, 2022

Journal: Journal of Radiology and Medical Imaging

Publisher: MedDocs Publishers LLC

Online edition: <http://meddocsonline.org/>

Copyright: © Mathew H (2022). *This Article is distributed under the terms of Creative Commons Attribution 4.0 International License*

Case description

A 28-year-old woman presented with slowly progressive weakness of the right upper limb since 14 years of age. This was purely motor, distally located and progressive in nature. It did not involve any other limbs. She also had a history of hypothyroidism and gestational diabetes. On examination, hypothenar muscle wasting and complete claw hand was noted (Figure 1) Power was reduced in muscles of the hand, while reflexes were bilaterally absent on both upper limbs. Distal asymmetric motor neuropathy was suspected, and nerve conduction studies confirmed the same. Plain MR imaging of the whole spine with dynamic flexion and extension of cervical spine was done which showed features consistent with Hirayama disease (Figure 2).

Hirayama Disease (HD) is a rare neurological condition characterised by sporadic juvenile muscular atrophy of the distal upper extremities, which predominantly affects the lower cervi-

cal cord. It mainly develops in the late teens and early twenties with a male preponderance ratio of about 3:1 [1]. Clinical features include insidious onset and slow progression of unilateral or bilateral muscular atrophy with weakness of the forearms and hands. Sensory disturbance, autonomic involvement, and Upper Motor Neuron (UMN) signs like hyperreflexia and hyper-tonia are rare. Diagnosis is based on the typical clinical features and dynamic MRI study when the neck is flexed. MR studies in flexion reveal anterior displacement of the posterior wall as well as an enhanced crescent-shaped lesion in the posterior epidural space of the lower cervical canal, which typically disappears when the neck returns to a neutral position [2]. MR imaging studies of the cervical spine in a neutral position shows features such as localised lower cervical cord atrophy, asymmetrical cord flattening, and loss of attachment between the posterior Dural sac and subjacent lamina, as well as non-compressed intramedullary high T2 signal intensity.



Cite this article: Mathew H, Ashwin KP. A Rare Case of Hirayama Disease Diagnosed by Dynamic MR Imaging. J Radiol Med Imaging. 2022; 5(1): 1066.

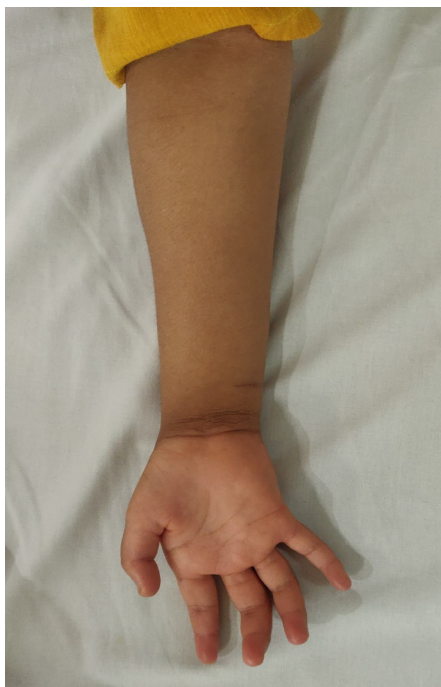

Figure 1: Wasting of hypothenar muscles of the right hand and complete claw hand.

On flexion imaging, there is anterior displacement of posterior dura with enlarged posterior epidural space (extends from the level of C₄ to C₇ vertebrae for a maximum length of ~5.4 cm and maximum thickness of ~4.8 mm) showing epidural flow voids. There is atrophy of lower cervical spinal cord, with associated intramedullary T2WI/ STIR hyperintensity involving the anterior horn of the spinal cord extending from C₄ to C₇ vertebrae. At all vertebral levels, mild diffuse disc bulge indenting the anterior thecal sac was seen, not resulting in neural foraminal narrowing.

References

1. Lay SE, Sharma S. Hirayama Disease (Non-progressive Juvenile Spinal Muscular Atrophy). StatPearls. 2019.
2. Anuradha S, Fanai V. Hirayama Disease: A Rare Disease with Unusual Features. Case Rep Neurol Med. 2016; 2016.

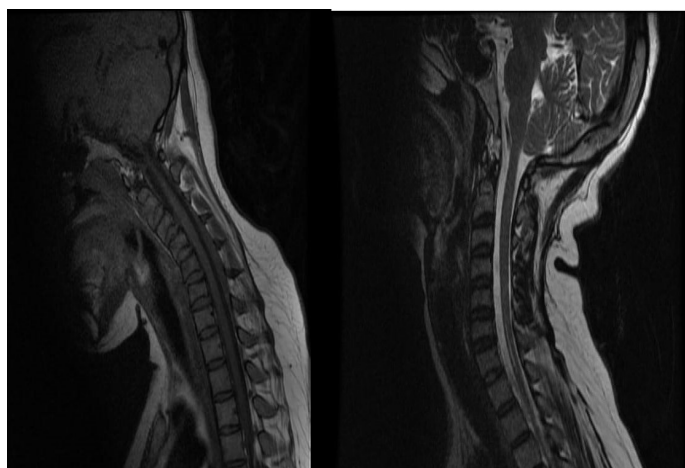


Figure 2: Craniovertebral junction is normal. Loss of cervical lordosis.